



Anatomy of lower extremity veins.

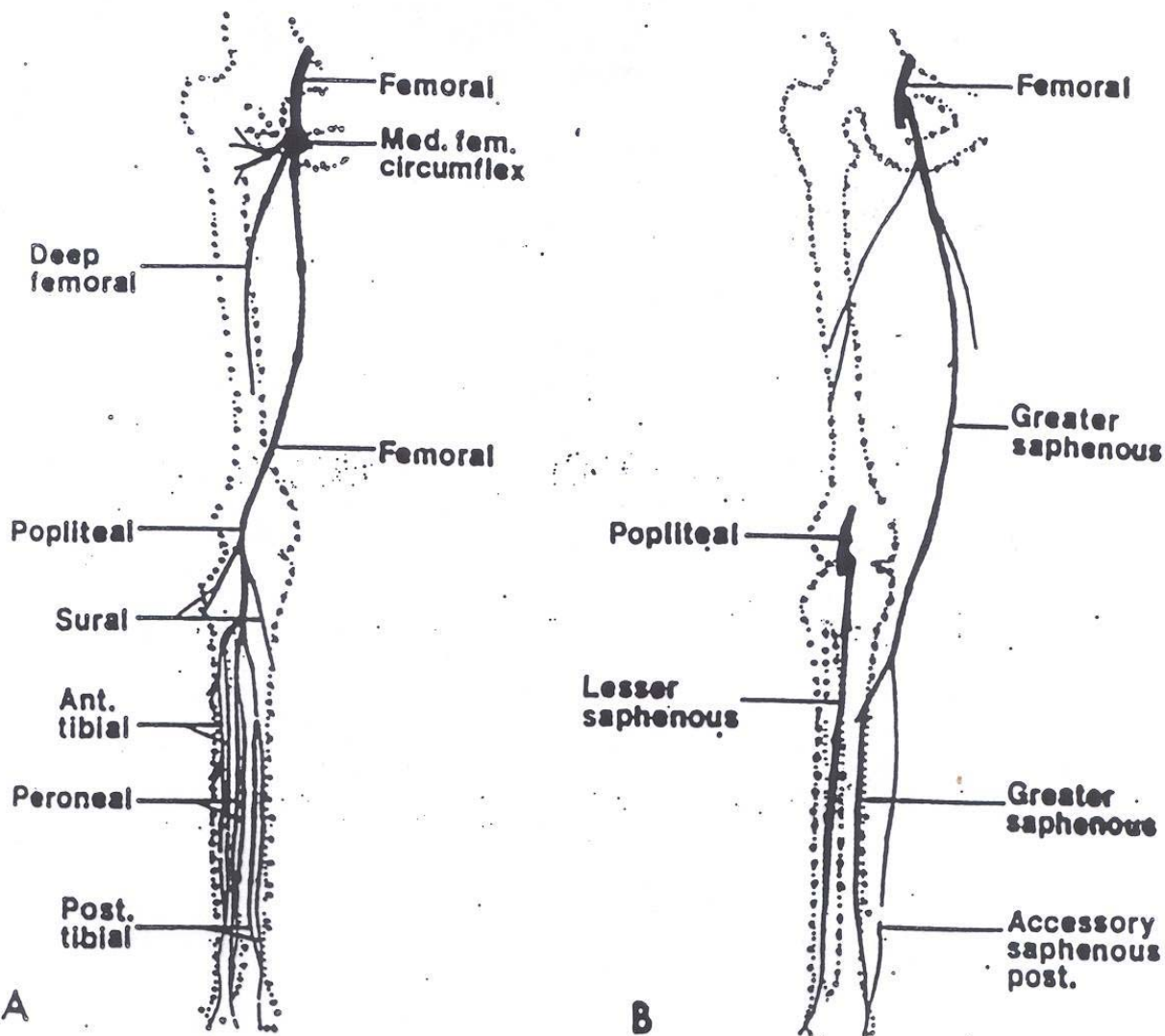


Fig. 15-1. Venous anatomy of the lower extremity. A) Deep venous system, and B) the superficial venous system.

NOTE THAT THE LEFT HAND SIDE ARE **DEEP VEINS**. THOSE *BELOW* THE POPLITEAL ARE DISTAL (CALF VEINS) THOSE *AT OR ABOVE* THE POPLITEAL ARE PROXIMAL VEINS